

# Study Seeks to Decode Focal Duodenal Necrosis

It's a worldwide intestinal affliction that's one of the top five diseases affecting caged and cage-free table egg layers in this country. Yet despite occurring in at least 10 states since first being recognized in Pennsylvania in 1997, Focal Duodenal Necrosis (FDN) remains a mystery.

FDN is found in all varieties of flocks, although clear signs and symptoms are not always present, suggesting that the disease may be underdiagnosed. The economic repercussions of the disease are easier to detect than its symptoms; FDN results in decreased egg production (ranging from 1 percent to 10 percent) and lowered egg weights (as much as 2.5 g per egg or 2 lb. per case).

With a grant from the Egg Industry Center, Dr. Monique S. Franca, assistant professor and Dr. Ana Maria Villegas, graduate student, in the Department of Population Health of the College of Veterinary Medicine at the University of Georgia, are pursuing a research project to more fully understand FDN's pathogenesis. Their fellow researchers are Dr. Roy Berghaus, Dr. Charles L. Hofacre and Dr. Margie Lee of the University of Georgia Poultry Diagnostic and Research Center, and Dr. Guillermo Zavala of Avian Health International.

"Although FDN is about 20 years old, the predisposing factors of this disease are still not completely known," Franca explains. "These research findings will provide much-needed information about possible factors and etiological agents that might be associated with FDN. A better understanding of this condition is needed to design control measures and intervention strategies to prevent FDN-associated egg production losses, and to improve the profitability of flocks affected with this disease."

Franca's research team designed a three-part study, beginning with questionnaires distributed among different U.S. layer operations to determine the epidemiological characteristics of flocks diagnosed with FDN. The survey also sought to develop a profile of affected flocks in terms of housing, rearing, management, nutrition, health status and methods used for disease prevention and control.

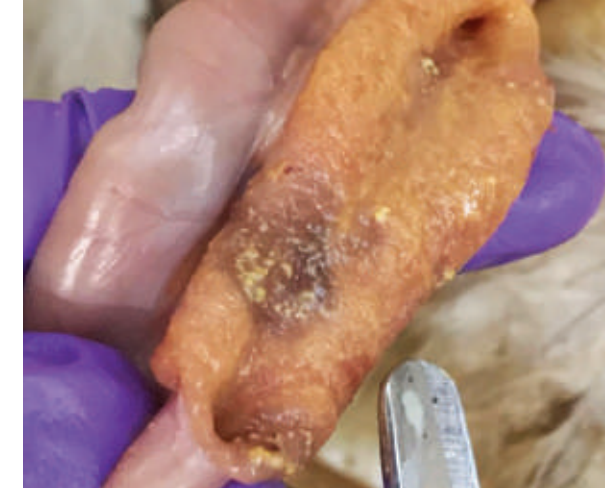The second part of the study involved obtaining duodenal samples from FDN-affected hens to test for the presence of various bacterial strains, including *Clostridium perfringens*, which previous research has shown plays an important role in the development of FDN.

Lastly, the "challenge model" portion of the research project, which is now ongoing, seeks to reproduce FDN in replacement pullets and determine the role of *C. perfringens* in the development of this condition. Pilot studies will be performed on 2- to 3-week old commercial chickens to evaluate the severity of the

disease reproduced under different variables. The entire research project will be completed sometime in 2018, and Franca is eager to compile and share her team's findings.

"I have always been intrigued by this condition, and as an avian pathologist I really enjoy problem-solving," Franca explains. "I have been very motivated to better understand FDN in order to help the egg industry control this disease. Intestinal disease pathogenesis is one of my favorite research topics, and my goal is to continue to conduct applied research on FDN and other poultry enteric diseases."

This is Franca's first Egg Industry Center grant and also the first grant she has received as principal investigator. "EIC support is very important and necessary for applied research to help solve the egg industry's challenges," she says. "I believe it would not be possible to advance the knowledge on Focal Duodenal Necrosis without EIC funding."



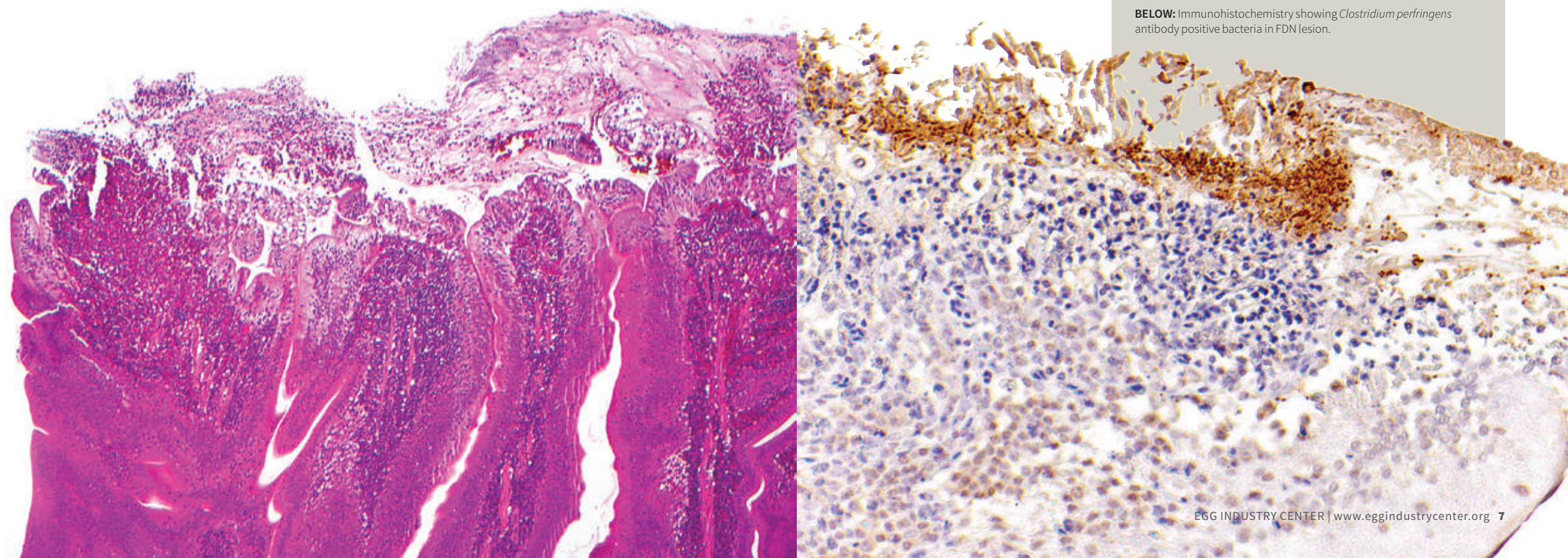
## PRELIMINARY FINDINGS INDICATE:

- FDN can occur in different breeds of egg layers and in birds of different age groups, with highest incidence during the peak and post peak of egg production.
- A majority of FDN affected flocks had frequent changes in feed formulation and use of distiller's dried grains with solubles.
- Disinfection alone of feeders, cages, walls and ceilings between flocks, without cleaning, may not be sufficient to prevent the persistency and transmission of FDN.
- *Clostridium perfringens* was the most abundant culture-isolated bacteria from lesions.
- Inoculation with *C. perfringens* isolated from FDN samples can cause mild gross and microscopic duodenal lesions suggestive of early FDN in experimentally infected chickens.

**ABOVE:** Macroscopic lesion of characteristic Focal Duodenal Necrosis lesion from a field trip to collect samples for this research project. Courtesy from Dr. Luke Baldwin (MAM candidate)

**BELOW, LEFT:** Histopathology of FDN lesion showing necrosis at the villus tip associated with numerous rod-shaped bacteria.

**BELOW:** Immunohistochemistry showing *Clostridium perfringens* antibody positive bacteria in FDN lesion.



Dr. Monique S. Franca