

HY-LINE NORTH AMERICA, LLC



Focal Duodenal Necrosis (FDN)

Bernie Beckman, DVM, Director of Technical Services for Hy-Line North America, LLC



FDN – Background

- Focal duodenal necrosis is an intestinal disease syndrome recognized in the USA for at least 15 years – Netherlands/Europe
- Found in all strains of layers – brown and white

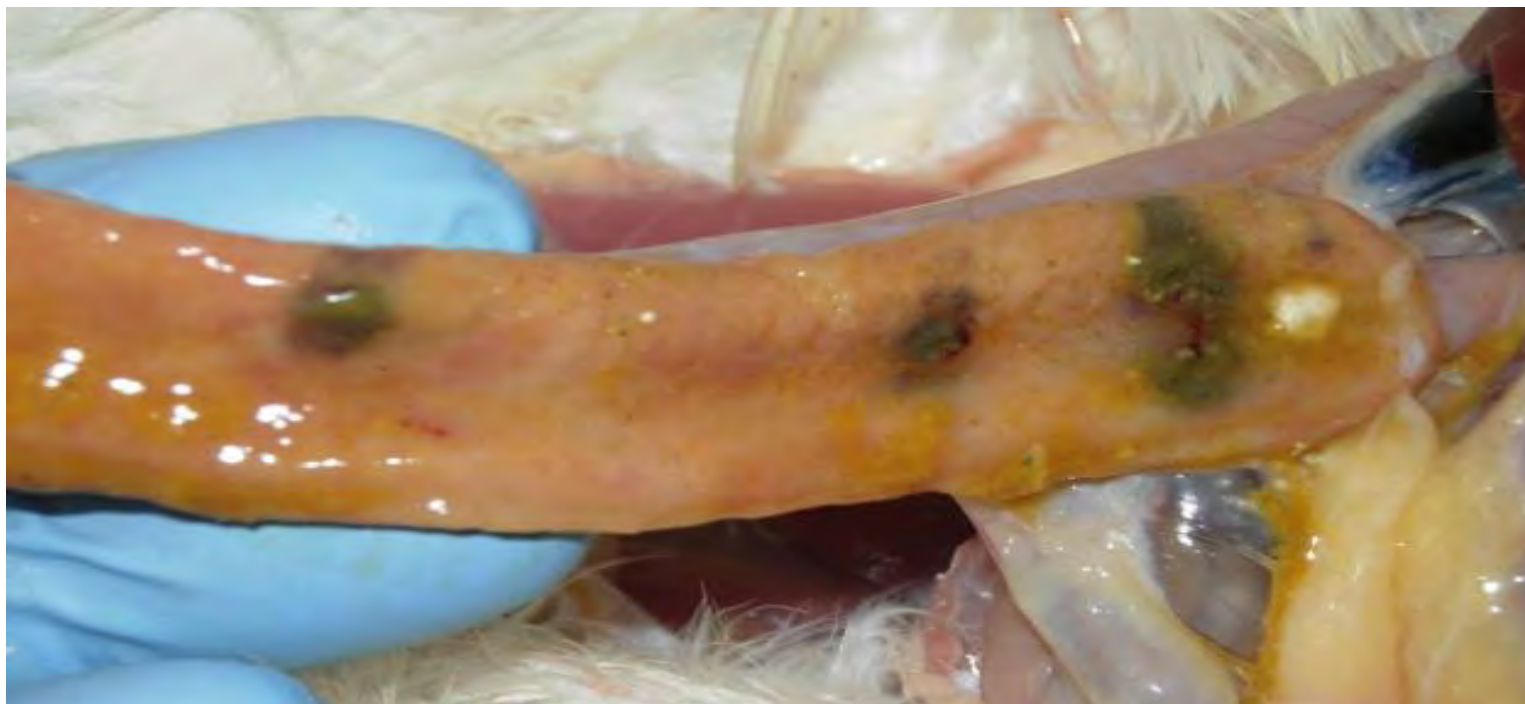


Image provided by Eric Gingerich, DVM. Diamond V, 2012.



- Producers on different farms and feeds affected – cage, cage free, organic flocks
- Seen in pullet flocks >14 weeks of age
- All stages of production
- The only “observable” clinical sign in birds is pale combs

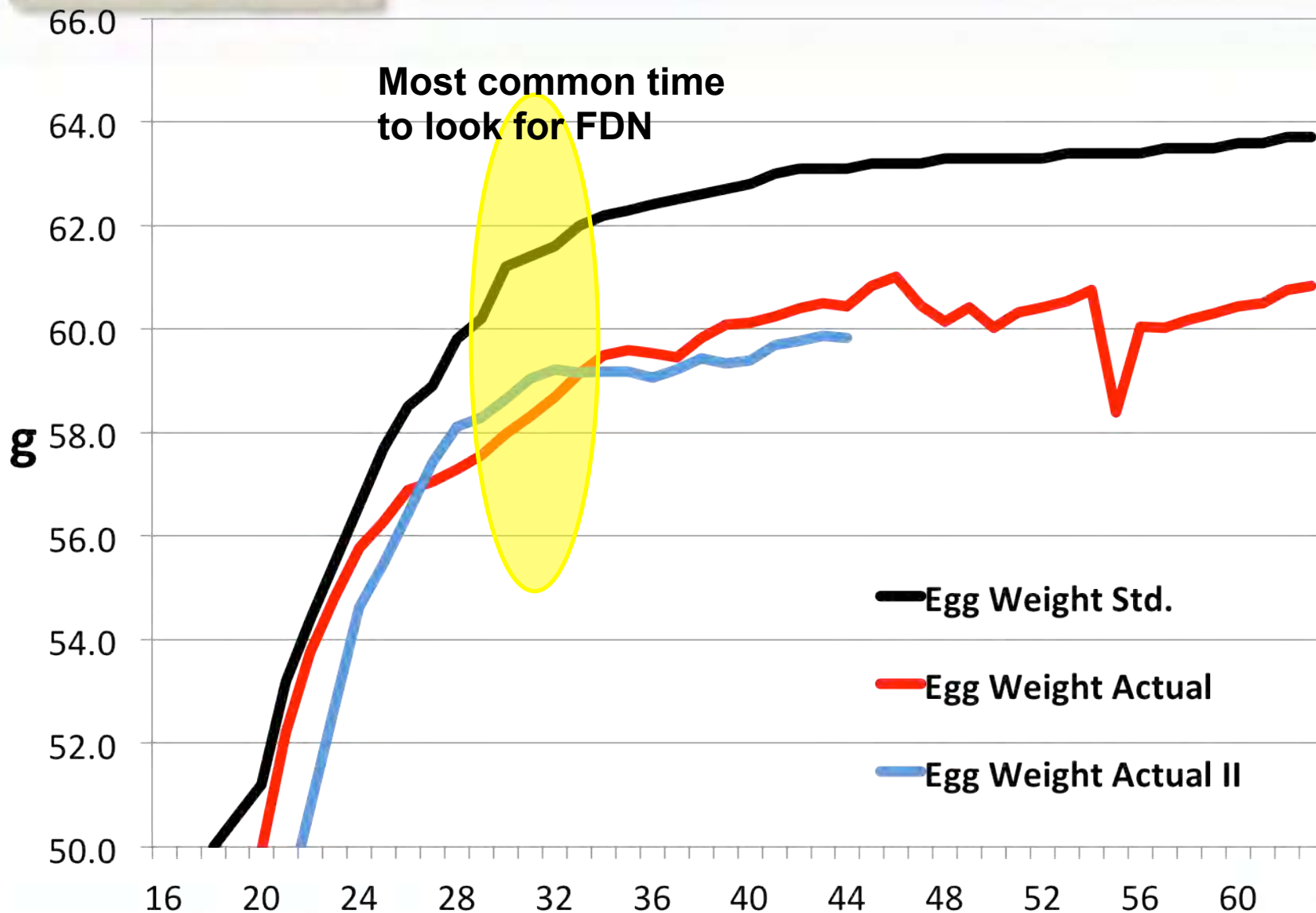


- Can recur in same flock after treatment
- 39% of flocks in spent hen study were positive – May 2000 to September 2001
- C&D wet wash and disinfectant not effective in reducing incidence

- Necropsy freshly euthanized birds or the lesions almost disappear
- Open duodenum within a couple of hours of expiration
- Commonly found on US complexes
- Drop in production up to 10%
- Drop in egg size
- *Slow to achieve desired egg weights*
- Birds with pale combs may increase the likelihood of finding FDN
- No increase in mortality



Egg Weight Issues with FDN

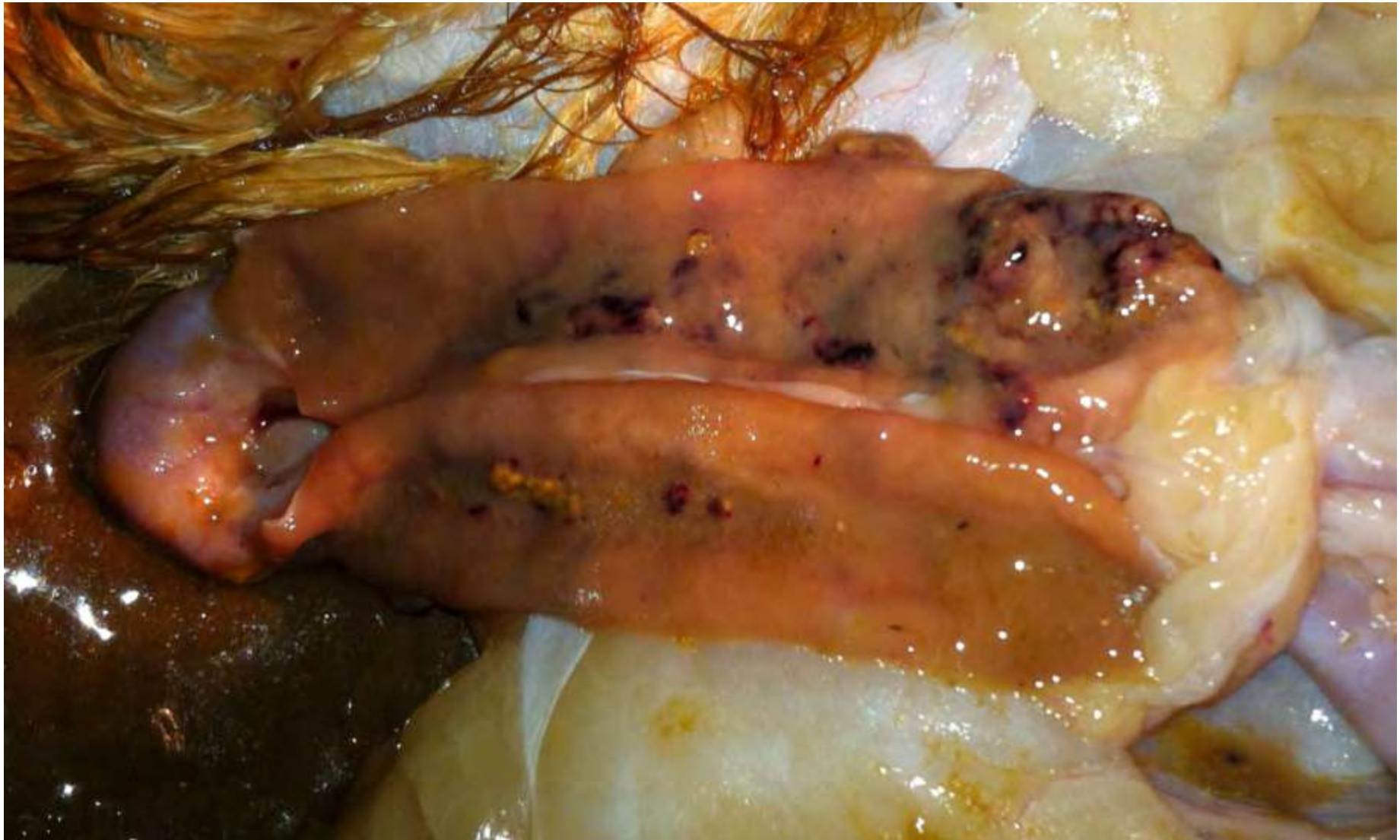

- Body weight gains up to 32 weeks, or body weight maintenance after peak, may be negatively affected
- Duodenum is a significant site of hormone-regulated active calcium absorption in laying hens

- Any damage to the cells in the duodenum could be expected to impair overall calcium absorption, thereby having potential consequences for bone and shell mineralization
- Duodenum is a major region of iron absorption which might explain the pale combs ± anemia of severely or chronically affected birds

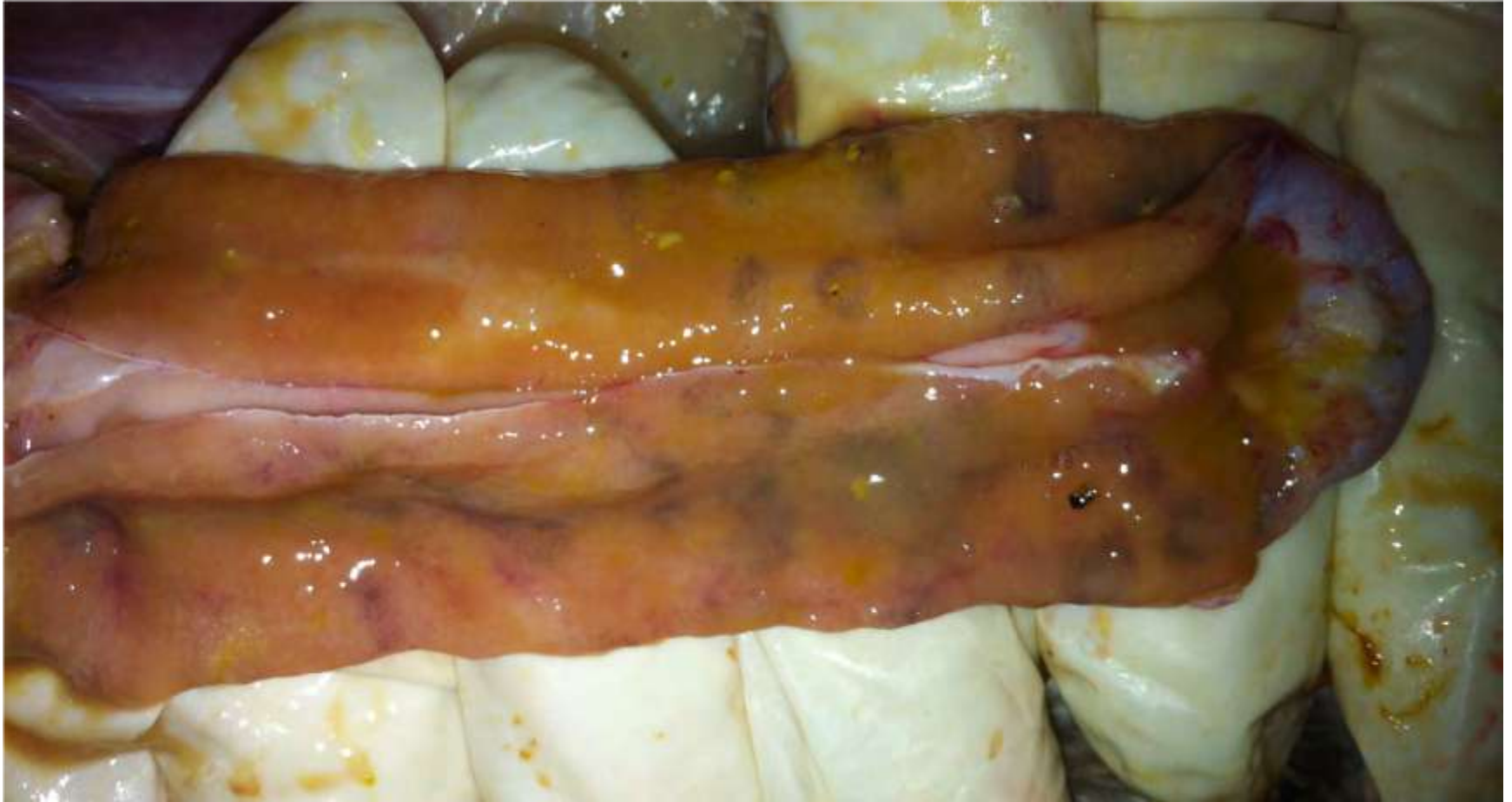

FDN!



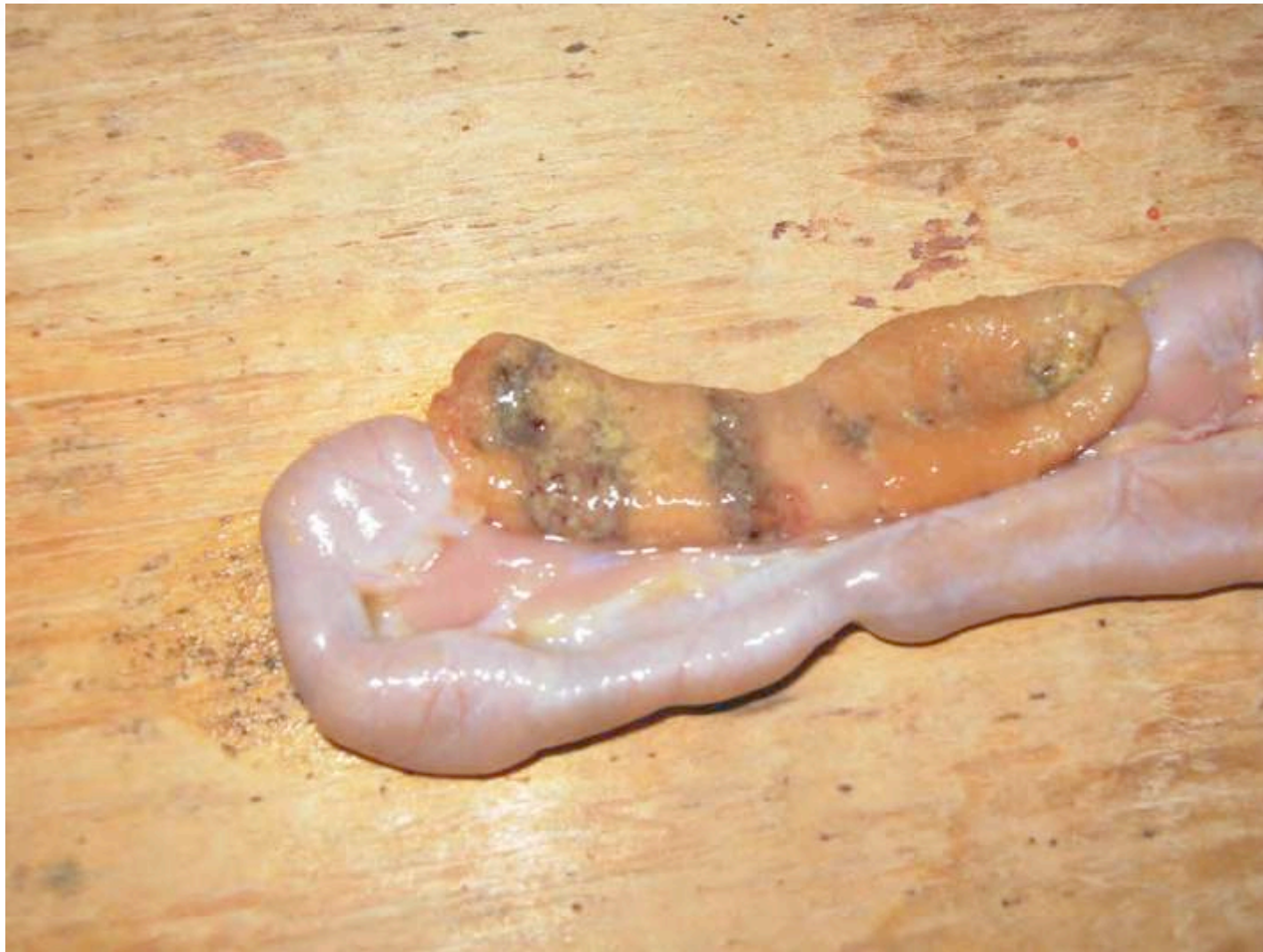

More FDN!



FDN Lesions

- Grey ulcerative areas in duodenal loop – single or multiple, irregular shaped 5-15 mm diameter areas
- Ulcers can extend down the intestine to the first section of the jejunum
- Hydrogen sulfide smell from duodenum
- Lesions include ulcerations and/or gray patches in the mucosa of the intestine
- Microscopic ulcerations populated with large gram positive bacteria and heterophilic inflammation

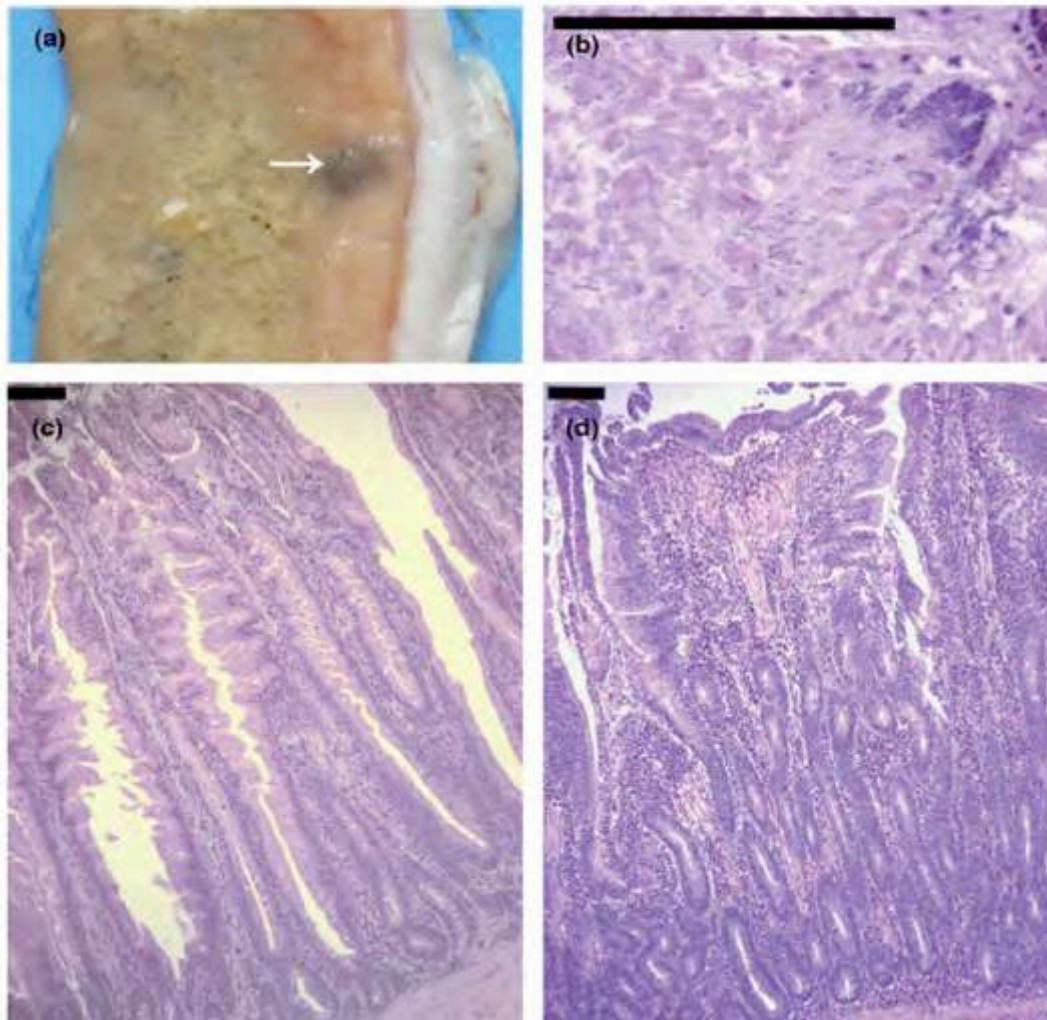




FDN Cause

- ???
- FDN responds to antibiotic treatment
- FDN found on all types of diets
 - Corn-soy
 - Corn-soy-meat and bone
 - Corn-soy-bakery meal
 - Corn-soy-canola

FDN in Avian Pathology



Janneke G. Allaart , Naomi D. de Bruijn , Alphons J. A. M. van Asten , Teun H. F. Fabri & Andrea Gröne (2012): NetB-producing and beta2-producing *Clostridium perfringens* associated with subclinical necrotic enteritis in laying hens in the Netherlands, *Avian Pathology*, 41:6, 541-546

FDN in Avian Pathology

- NetB-producing and beta2-producing *Clostridium perfringens* associated with subclinical necrotic enteritis in laying hens in the Netherlands
- 19.2% of affected birds had no observable lesions
- 24.7% of affected birds had observable gross necrosis lesions
- 56.2% of affected birds had abnormal liquid contents
- *Clostridium perfringens* was isolated from 26% of birds
- All birds had histopathological abnormalities
- FDN has traditionally been associated with *Clostridium colinum*

FDN – Cause

- Bacterial isolation – Gram variable, slow-growing, long filamentous anaerobe isolated at Auburn University
- FDN seen with or without tapeworms
- Virus isolation negative to date
- No spirochetes found in lesions
- No associated mycotoxins in feed
- No biogenic amines in feed

FDN – Treatment Options

- BMD is the first, second, and third option
 - Used at 25 g/ton feed for 4 weeks and longer, if needed
- Chlortetracycline is also used with success
- Treatment is usually started when egg weights are affected or production is very poor
- Treatment with penicillin has worked well in the past, when approved
- Alternative products such as organic acids are being explored
- Probiotics – Prevention/Treatment
- Tylosin – Prevention/Treatment

FDN – Economic Effect

- Loss of egg income due to lowered egg weights
- As much as 2.5 g per egg/2 lbs per case
- Egg production may be below standard by up to 10% or appear normal
- Cost of medication



FDN – Loss of Egg Income

- Assume 21 days of lower egg weight class category (large vs. medium)
- Assume 7 cent spread
- For a 100,000 bird flock = \$9800



FDN – Effects

- Total cost of an outbreak of 100,000 birds in early lay
 - Treatment cost = \$1483
 - Egg income loss = \$9800
 - Total = \$11,283 or 11.3 cents per bird

Preventative Medication

- Add medication from housing to 40 weeks
- Bactracin (25 g/ton)
- Probiotic (0.5 lb/ton) from 20 to 40 weeks
- Total cost for 100,000 birds = \$4218 or 4.2 cents per bird

- Routine monitoring
 - 5 to 10 birds necropsied
 - Select at random or select pale birds
 - Treat only when found
- OR
- Use preventative medication



Preventative Medication vs. Treatment

4.2 cents/bird

vs.

11.3 cents/bird

- * At some complexes it is almost every flock needing treatment; but at others, it is more on a house by house situation

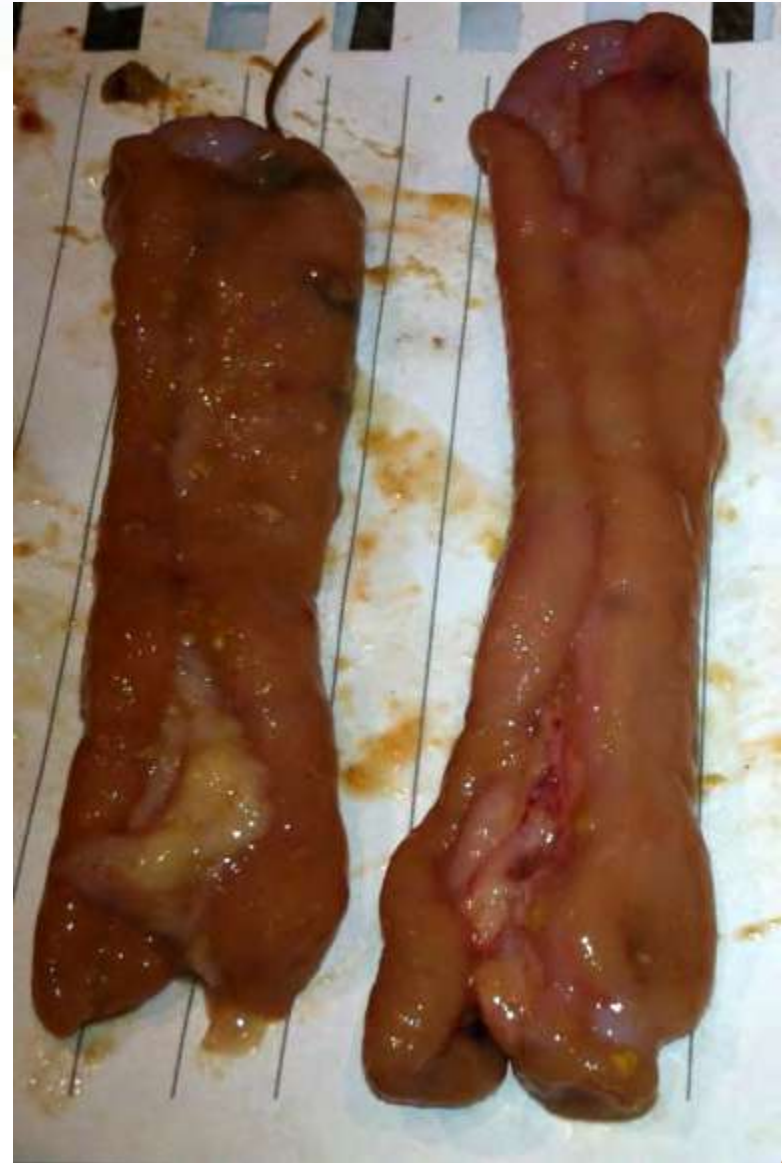

FDN – Summary

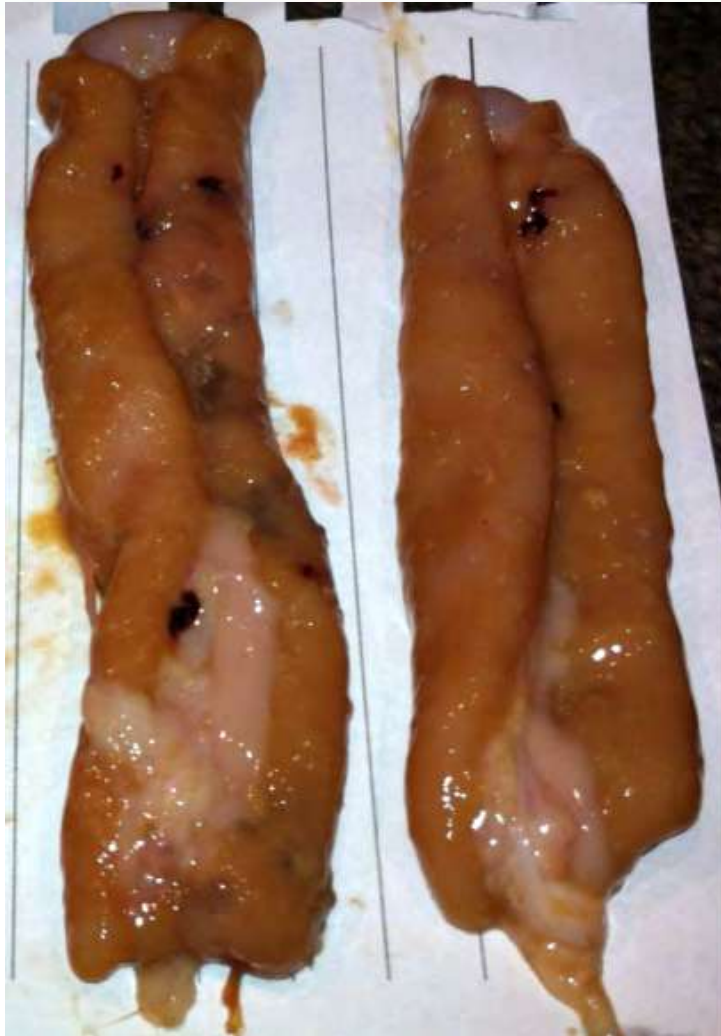- No proven cause of FDN although it is closely associated with clostridium infection
- Evidence *Clostridium perfringens* and/or *colinum* are involved
- Most antibiotics that are effective against Gram+ bacteria will efficiently treat FDN

Conclusions

- Limited availability of non-withdrawal antibiotics, and very few affordable options



Conclusions



- Freshly euthanized birds must be necropsied to find FDN
- Overall more investigation is required
- Additional treatment options need to be explored
- Closer attention to intestinal health is important